



एचएलएल लाइफकेयर लिमिटेड  
(भारत सरकार का उद्यम)

 HLL Lifecare Limited  
(A Government of India Enterprise)

**AMRIT PHARMACY ORTHOPAEDICS IMPLANTS AIIMS**

C/o HLL LIFECARE LTD  
(A GOVT OF INDIA ENTERPRISE)

GSTIN: 07AAACH5598K123

**ESTIMATED QUOTATION**

PATIENT NAME	SHAHINA	DATE OF CHALLAN	23-05-2026	
BIS/MRD NO.	108698055	DOCTOR'S NAME	DR SA KHAN	
DEPARTMENT	ORTHOPAEDICS	CHALLAN NO.	2627/874	
SNO	DISCRIPTION	QTY	PRICE	REMARKS
PARTICULARS (PITKAR)				
1	5.0mm PROXIMAL FEMUR PLATE	1	36150	
2	5.0mm LOCKING HEAD SCREW	2	2711	
3	4.5mm CORTICAL SCREW	2	2119	
4	3.5mm SMALL LCP PLATE	1	8134	
5	3.5mm LOCKING HEAD SCREW	2	2982	
6	3.5mm CORTICAL SCREW	2	1626	
TOTAL AMOUNT			53722	

BANK DETAILS HLL LIFECARE LTD.  
IFSC CODE HDFC0000996  
ACCOUNT NO. 09960330000108

AUTHORIZED SIGNATORY

ALL DISPUTES ARE SUBJECT TO DELHI JURISDICTION

GOODS ONCE SOLD WILL NOT BE TAKEN BACK

AMRIT PHARMACY ORTHOPAEDICS IMPLANTS AIIMS HOSPITAL





# Friends

X-RAY CENTRE  
**DIAGNOSTICS & IMAGING**  
AN ISO 9001 : 2008 CERTIFIED COMPANY


Mob : 8076384701  
Email : [akgfriends@gmail.com](mailto:akgfriends@gmail.com)  
Website : [www.friendsxray.com](http://www.friendsxray.com)



• ECHO COLOUR DOPPLER • 2D ECHO • TMT • STRESS ECHO • ULTRASOUND 2D & 3D  
• E.C.G. • DIGITAL X-RAY • D.P.G. X-RAY • COMPUTERISED LABORATORY

Patient ID : 102513308  
Patient Name : **Baby SHAHINA**  
Gender / Age : Female / 7 Yrs  
Refd By : Dr. A.I.M.S  
PHID No : P10100011962

Registered On : 03/11/2025 15:35:36  
Released On : 03/11/2025 18:54:02  
Printed On : 03/11/2025 18:54:06



### X- RAY CHEST PA VIEW

- Both lung fields are clear.No parenchymal lung lesion is seen
- Both hilar shadows are normal.
- Cardiac shadow is normal in contour & outline
- Both CP angles are clear.
- Soft tissue of chest and bony thorax under view are normal.

**IMPRESSION:- NORMAL STUDY.**

Please co-relate clinically.

**Dr. ARVIND CHAUDHARY**  
MBBS, M.D.  
Consultant Radiologist  
DMC No. 21229

Dr RISHI RAJ SINGH  
Consultant Radiologist  
DMC No. 78403

DR ABHISHEK UDAY  
MD, Radiodiagnosis  
DMC.NO. 64606

Dr ARVIND CHAUDHARY  
Consultant Radiologist  
DMC No. 21229

Dr SAMRIDDHI  
Consultant Radiologist  
DMC/R/9083

**WEEKDAY TIMING : 8:00 AM TO 8:00 PM - SUNDAY TIMING : 8:00 AM TO 2:00 PM**



ECHS EMPANELLED



CGHS EMPANELLED

PATIENT'S NAME: <b>SHAHINA</b>	AGE/SEX: <b>7y6m/Female</b>
REF. BY: <b>DR. AIIMS</b>	REG./UID: <b>SHA7836</b>
PATIENT'S REF: <b>(None)</b>	EXAM. DATE: <b>09-MAY-2026</b>

## MRI RIGHT HIP, THIGH WITH KNEE JOINT WITH CONTRAST

### **TECHNIQUE:**

SPIN ECHO T1W, T2W, PD AND STIR SAGITTAL IMAGES OF RIGHT HIP, THIGH WITH KNEE JOINT WERE OBTAINED AND CORRELATED WITH T2W AXIAL, AND T1W AND T2W CORONAL IMAGES. POST CONTRAST IMAGES IN AXIAL, CORONAL AND SAGITTAL PLANES

*Follow up case of Ewing sarcoma.*

### **FINDINGS:**

**There is intramedullary heterogeneous altered signal intensity seen in the proximal right shaft of femur with overlying periosteal reaction with cortical thickening and mild overlying cortical irregularity, showing subtle patchy enhancement on post contrast images and minimal surrounding free fluid, likely post treatment changes. No evidence of any surrounding soft tissue is noted.**

Rest of visualized bones are normal in signal intensity.

Anterior and posterior cruciate ligaments appear normal in contours and signal intensity pattern.

Medial and lateral collateral ligaments appear normal in contours and signal intensity pattern.

Medial and lateral menisci appear normal in contours and signal intensity pattern.

Patellar ligament and quadriceps tendon are normally visualized.

Rest of visualized muscles and soft tissues appear grossly normal.

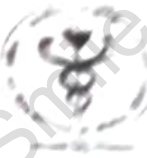### **IMPRESSION: MR study reveals:-**

- Intramedullary heterogeneous altered signal intensity in the proximal right shaft of femur with overlying periosteal reaction with cortical thickening and mild overlying cortical irregularity, showing subtle patchy enhancement on post contrast images and minimal surrounding free fluid, likely post treatment changes. No evidence of any surrounding soft tissue.**

*Please correlate clinically.*

— End of the Report —

**Disclaimer:** It is an interpretation of medical imaging/diagnostic based on clinical data which is being provided in an electronic format which does not require any physical signatures. All modern machines/procedures have their own limitation. This is neither complete nor accurate; hence, findings should always be interpreted in the light of clinico-pathological correlation. This is a professional opinion, not a diagnosis. Not meant for medico legal purposes. Any typographical error should be informed and report sent for correction within 7 days.



**<sup>18</sup>F-FDG WHOLE BODY PET-CT STUDY**

<b>Patient Name: SHAHINA</b>		<b>Age/Sex: 7Y/F</b>
<b>Study ID: FDGN/42383/25</b>	<b>UHID: 108698055</b>	<b>Date: 27.11.2025</b>
<b>Indication: c/o right femoral Ewing sarcoma, PET/CT for baseline evaluation.</b>		

**Procedure:** PET-CT acquisition was done 60 minutes after injection of  $7\text{mCi}^{18}\text{F-FDG}$  by intravenous route, from the level of vertex to mid-thigh. CT was done for attenuation correction and anatomical localization

**PET-CT Findings:**

**Head and Neck:** Increased tracer uptake noted in bilateral palatine tonsils with few sub-centimetric cervical IA and bilateral cervical II lymph nodes – reactive. Visualized paranasal sinuses, skull base, pharynx, larynx, thyroid and rest of the neck region do not show any abnormality on CT.

**Thorax:** Few non FDG avid sub-centimetric bilateral axillary lymph nodes noted with preserved fatty hilum – likely benign. Few subcentimetric right upper & lower paratracheal, subcarinal and bilateral hilar lymph nodes noted, with no significant tracer uptake – likely reactive. Physiological FDG uptake is seen in the thymus. Lungs, large airways, pleura heart, great vessels and other mediastinal structures appear normal on CT.

**Abdomen-Pelvis:** FDG avid subcentimetric right external iliac and right inguino-femoral lymph nodes noted- ?reactive ?involvement. Few non tracer avid sub-centimetric bilateral inguinal lymph nodes noted with preserved fatty hilum – likely benign. Normal radiotracer distribution is noted in the spleen, liver, small bowel, kidneys and urinary bladder.

**Musculo-Skeletal System:** Large ill-defined sclerotic expansile lesion with periosteal reaction, intramedullary sclerosis and large soft tissue component, infiltrating overlying vastus muscle noted involving proximal one third of shaft of right femur (soft tissue component measuring  $\sim 8.1 \times 4.7\text{cm}$ ). Focal increased FDG uptake noted in right ischial tuberosity and right ala of sacrum- ?marrow metastases. Physiological FDG distribution is seen in rest of the visualized axial and appendicular skeleton.

**IMPRESSION:**

- Metabolically active lesion with periosteal reaction, intramedullary sclerosis and large soft tissue component involving proximal one third of shaft of right femur- consistent with known primary.
- Focal marrow hypermetabolism in right ischial tuberosity and right ala of sacrum- ?marrow metastases- adv. MR correlation.
- Metabolically active subcentimetric right external iliac and right inguino-femoral lymph nodes - ?reactive ?disease involvement.

  
Dr. Nivedita Kundu  
Senior Resident

  
Prof. Rakesh Kumar  
Consultant



अ० भा० आ० सं० अस्पताल / A.I.I.M.S. HOSPITAL  
बहिरंग रोगी विभाग / Out Patient Department



अस्पताल के अन्दर धूम्रपान मना है। / SMOKING IS PROHIBITED IN HOSPITAL PREMISES

अस्थिरोग विभाग / UHID: 108698055

कमरा / Room C-111

OPR-6



Queue / संख्या F81  
Unit-II, Orthopedics.

Dept No: 20250080047709

10रो०वि० पंजीकृत सं०/O.P.D. Regn. No. \_\_\_\_\_

शाहिना शाहिना / SHAHINA SHAHINA

आयु Age

पता / Address

D/O RISHU RAM  
7Y 6M 28D / F/(महिला)  
H 516 SHAKUR PUR, DELHI, Pin:0, INDIA

सोम, बुध, शुक्र,



Reporting: 10:36:59  
22/05/2026

Ph: 8595079029 General Rs. 0  
Follow Up Patient

निदान/Diagnosis

दिनांक/Date

उपचार/Treatment

*Esing saevum @ femur*

*1 ERAC ↓ pedo suo  
last chens → 19/4/26*

*Adv c/dme prof SA Khan Sir  
- will need AK + ECRT.*

*→ Enclosed is the name of Prof SA Khan*

*4 @ RBC*

~~*Reverse is*~~

*Reverse is*

*Estimate: →*

*Proximal femur: locking  
plate x 1  
+ 1. x 3.5 mm L&P*

*164  
Jaswan*

*AOSYS → AMRIT PHARMACY*

*Dr. Divyati Deepita Rano  
Fellow Musculoskeletal Oncology  
Department of Orthopedics  
AIIMS, New Delhi-110029  
DMC Reg. No. 97217*



CLEAN AND GREEN AIIMS / एम्स का यही संकल्प, स्वच्छता से काया कल्प  
अंगदान-जीवन का बहुमूल्य उपहार / ORGAN DONATION - A GIFT OF LIFE  
O.R.B.O., AIIMS, 26588360, 26593444, www.orbo.org Helpline - 1060 (24 hrs service)





**<sup>18</sup>F-FDG WHOLE BODY PET-CT STUDY**

Patient Name: SHAHINA		Age/Sex: 7Y/F
Study ID: FDG/41340/26	UHID: 108698055	Date: 14.05.2026
Indication: c/o Right femoral Ewing's sarcoma s/p excision and right intramedullary femoral nailing and CT (19.04.2026).Recent bone marrow: free form tumor. PET/CT for response assessment/current disease status.		

Procedure: PET-CT acquisition was done 60 minutes after injection of 10mCi <sup>18</sup>F-FDG by intravenous route, from the level of vertex to mid-thigh.

**PET-CT Findings:**

Head and Neck: Dental artefact noted obscuring regional anatomy. Mucosal thickening noted in bilateral maxillary sinuses. Faint tracer uptake noted in bilateral palatine tonsils and nasopharynx. Faintly FDG avid to non-avid multiple sub-centimetric bilateral cervical II-V lymph nodes – reactive/infective.

Thorax: Few non FDG avid sub-centimetric bilateral axillary lymph nodes noted with preserved fatty hilum – likely benign. Few mildly FDG avid calcific subcentimetric to enlarged bilateral paratracheal, subcarinal and bilateral hilar lymph nodes noted – likely reactive/post infective. Mild fibrotic changes in bilateral lung fields- likely infective. Patchy atherosclerotic changes noted in arch of aorta, descending aorta and coronary arteries. Physiological FDG uptake is seen in the myocardium.

Abdomen-Pelvis: Liver measures 14.0cm in CCS with diffuse FDG uptake and no focal lesion on CT. Few non FDG avid subcm sized multiple retroperitoneal and mesenteric lymph nodes noted – likely benign. Few non-tracer avid bilateral inguinal and bilateral external iliac lymph nodes noted.

Musculo-Skeletal System: Mildly FDG avid soft tissue thickening (measuring ~ 1.6 x 1.0cm vs 8.1x4.7cm in size) noted in anterior compartment of right proximal thigh with subtle sclerosis in adjacent femur bone. Diffuse increased FDG uptake noted in the visualized axial and appendicular skeleton with no focal lesion – likely reactive.

**IMPRESSION:**

- Mild metabolically active soft tissue thickening in anterior compartment of right proximal thigh - minimal residual disease.
- As compared to previous PET/CT study (FDGN/42383/25, dated: 27.11.2025), there is significant reduction in extent of primary lesion and metabolic resolution of lymph nodes- likely near complete metabolic response to therapy.

  
Dr. Vidhya  
Senior Resident

  
Dr. Kh. Bangkim Chandra  
Consultant



अखिल भारतीय आयुर्विज्ञान संस्थान, नई दिल्ली  
ALL INDIA INSTITUTE OF MEDICAL SCIENCES, NEW DELHI  
DEPARTMENT OF PATHOLOGY



MC-7788

Patient Name : SHAHINA  
Accession No : S2625326  
Age/Sex : 7 Y /Female  
Clinic/Dept : Paediatrics  
Consultant Incharge : Dr. Rachna Seth

UHID NO. : 108698055  
F/H Name : D/O RISHU RAM  
Additional ID : NA  
Unit : Unit II  
Request Date/Time : 11-05-2026 /10:02:05  
Receiving Date/Time : 11-05-2026 /14:18:13

### HISTOPATHOLOGY REPORT

#### GROSS EXAMINATION:

Accession No. : S2625326A

Specimen: Bone marrow biopsy (Right)  
Received four pieces of linear cores of bony tissue measuring (cumulative length) 1 cm.

Accession No. : S2625326B

Specimen: Bone marrow biopsy (Left)  
Received four pieces of linear cores of bony tissue measuring (cumulative length) 0.5 cm.

#### MICROSCOPIC EXAMINATION:

Bilateral bone marrow biopsies are fragmented and shows cellularity of approximately 70% with hematopoietic cells of all three series.

There is no evidence of malignancy in the sections examined in both the biopsies.

Note: Patient is a known case of Ewing sarcoma - vide clinical history and histopathology accession number S2559708

#### DIAGNOSIS:

S2625326A	Bone marrow biopsy	Right	• <u>No evidence of malignancy</u>
S2625326B	Bone marrow biopsy	Left	• No evidence of malignancy

End Report

Reporting Resident: Dr. Vanlalhruijii

Reporting Faculty: Dr. Rachana Meena, M.D.  
Assistant Professor

Reporting Date/Time: 16-05-2026 14:29

#### Disclaimer :

- This report is based on the tissue submitted and examined. The findings should be interpreted in conjunction with clinical, radiological, and other laboratory data. Ancillary studies (immunohistochemistry, special stains, molecular tests) are interpreted within technical limitations. The diagnosis pertains only to the material received; if there is any clinical-pathological discrepancy, repeat sampling or further evaluation is recommended.
- As per laboratory policy, paraffin blocks and stained slides are retained for 10 years. Remaining formalin fixed tissue samples are preserved for 2 weeks after issue of



भारत सरकार  
GOVERNMENT OF INDIA



Shahina  
DOB: 24/08/2018  
FEMALE

**3004 2608 1233**  
VID : 9110 7543 9901 1304

**मेरा आडधार, मेरी पहचान**